



Case Report

Endoscopic Treatment of Foreign Body Colouterine Perforation: A Case Report



Maxwell M. Chait^{1,2*} and Naveed A. Chaudhry³

¹Department of Medicine, Vagelos College of Physicians and Surgeons, Columbia University, New York, NY, USA; ²Department of Medicine, White Plains Hospital, White Plains New York, NY, USA; ³Department of Medicine, Icahn School of Medicine at Mount Sinai, New York, NY, USA

Received: September 11, 2023 | Revised: July 02, 2024 | Accepted: July 17, 2024 | Published online: September 02, 2024

Abstract

A colouterine fistula is an extremely rare condition that has been reported in various diseases, including diverticulitis, sigmoid colon malignancy, and complications from radiotherapy. It can also arise from iatrogenic conditions such as the insertion of intrauterine devices, endometrial curettage with urinary tract and bowel perforation, and obstetrical injury. Although colovaginal fistula caused by a foreign body has been reported, colouterine perforation by a foreign body has not been previously documented. We report the first case of foreign body colouterine perforation and its successful treatment by endoscopic removal and repair, resulting in the complete resolution of symptoms without the need for surgery. This case is highly significant due to its rare occurrence and successful treatment by endoscopic removal and repair without the usual and expected necessity for surgical intervention.

Introduction

Gastrointestinal (GI) tract perforation by an ingested foreign body occurs in less than 1% of cases and can be a serious, life-threatening condition.^{1,2} Colouterine fistula is an extremely rare condition because the uterus is a thick, muscular organ. It has been reported in various diseases such as diverticulitis, sigmoid colon malignancy, radiotherapy, and iatrogenic conditions such as the insertion of intrauterine devices, endometrial curettage with urinary tract and bowel perforation, and obstetrical injury.^{3–5} Although colovaginal fistulae have been reported as a result of foreign bodies,⁶ there is no previous record of a foreign body causing colouterine perforation. We report the first case of foreign body colouterine perforation and its successful treatment by endoscopic removal and repair, resulting in the complete resolution of symptoms without the need for surgery. This case is highly significant due to its rare occurrence and successful treatment by endoscopic removal and repair without the usual and expected necessity for surgical intervention. It demonstrates that endoscopic therapy should be considered as an alternative ap-

proach to surgery in patients with accessible lesions and without significant contraindications.

Case presentation

An 85-year-old woman presented with a two-week history of intermittent left lower quadrant pain and diarrhea. The pain progressively increased in severity and frequency and radiated to the rectum. She had been seen at another hospital emergency department, where a CT scan of the abdomen and pelvis revealed a 3.9 cm radiopaque linear density within the sigmoid colon, suggesting a foreign body. She was discharged home without intervention, with a recommendation for a follow-up reimaging CT scan of the abdomen on an outpatient basis. Her past medical history included diverticulosis coli, gastroesophageal reflux disease, irritable bowel syndrome, dementia, hypertension, hyperlipidemia, rheumatoid arthritis, and cerebrovascular disease. Six days later, she was seen by her physician with continued abdominal pain radiating to the rectum and diarrhea and was then referred immediately to the hospital emergency department. Physical examination revealed left lower quadrant abdominal tenderness without guarding or rebound tenderness. Laboratory tests, including CBC (complete blood count) and complete metabolic panel, were unremarkable. A CT scan of the abdomen and pelvis with IV contrast revealed a 3.7 cm slightly obliquely vertically oriented tubular radiopaque structure centered within the sigmoid colon lumen, suggestive of a foreign body. The cephalad tip of the presumed foreign body appeared within the lumen or wall of the mid-sigmoid colon. The caudal tip appeared to extend beyond the sigmoid colon wall, through the adjacent mes-

Keywords: Endoscopy; Digestive System; Colonoscopy; Gastrointestinal; Colon Perforation; Uterine Perforation; Foreign Body Migration; Endoscopic Surgical Procedure; Procedure; Colonoscopy Surgery; Endoscopic.

*Correspondence to: Maxwell M Chait, Department of Medicine, Vagelos College of Physicians and Surgeons, Columbia University, 15 North Broadway, New York, NY 10601, USA. ORCID: <https://orcid.org/0000-0000-2-4700-6421>. Tel: +01-914-428-6000, Fax: +01-914-946-3328, E-mail: maxwellchait@gmail.com

How to cite this article: Chait MM, Chaudhry NA. Endoscopic Treatment of Foreign Body Colouterine Perforation: A Case Report. *J Transl Gastroenterol* 2024;2(3):173–176. doi: 10.14218/JTG.2023.00076.

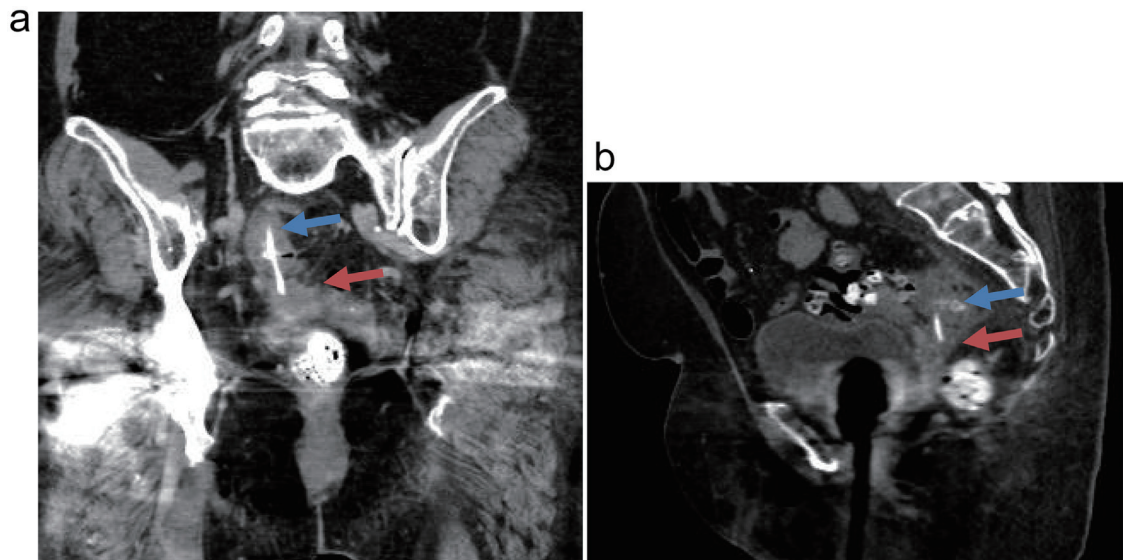


Fig. 1. CT scan images. Coronal (a) and sagittal (b) CT images of the pelvis show a vertically oriented radiopaque foreign body within the sigmoid colon. The proximal tip of the foreign body is positioned within the sigmoid colon lumen (blue arrow), and the distal tip is within the uterus (red arrow). The foreign body traverses a thin band of intersecting pelvic fat.

enteric fat, with the tip appearing within the lower uterine segment, possibly within a diverticulum. The uterus was otherwise unremarkable. There was mild wall thickening of the sigmoid segment, with adjacent fluid and small, likely reactive lymph nodes. There was no pneumoperitoneum appreciated (Fig. 1).

The patient was admitted to the hospital for further intervention, and a surgical consultation was obtained. Due to the mental and physical status of the patient, the surgical consultant requested a gastroenterology consultation for an attempt at endoscopic removal of the foreign body. The patient was placed on IV fluids and broad-spectrum antibiotics and prepared for colonoscopy.

A colonoscopy was performed with the CFHQ 190L Olympus colonoscope to the level of the cecum without difficulty. A large foreign body, which appeared to be a chicken bone with surrounding edematous thick mucosal folds, was found perforating through the colonic wall in the mid-sigmoid colon and wedged into the opposing colonic wall (Fig. 2a). The end wedged into the opposing colonic wall was teased out with the Raptor grasping device forceps and the large radial jaw biopsy forceps. A 13 mm snare was placed around the foreign body, and it was removed with gentle

traction of the colonoscope in a retrograde fashion. The colonoscope was reinserted, and two clips were placed at the site of the perforation (Fig. 2b). A nearby 3 mm colonic polyp was excised with cold biopsy forceps as well. Multiple medium-mouthed diverticula were found throughout the entire colon. Pathologic review revealed an animal bone 4.2 cm in length with a diameter ranging from 0.2–0.4 cm (Fig. 2c).

The patient had a complete resolution of all symptoms. A repeat CT scan of the abdomen and pelvis one week later revealed that the previously seen linear foreign body within the sigmoid colon was no longer evident. Colonic diverticulosis was noted, and metallic clips were present in the sigmoid colon from the recent intervention. There was no peri-colonic free air or fluid collection.

Discussion

GI tract foreign body ingestion occurs commonly.^{1,2} Previous studies have shown that more than 80% of foreign objects will pass spontaneously without the need for intervention. GI tract perforation by an ingested foreign body occurs in less than 1% of cases

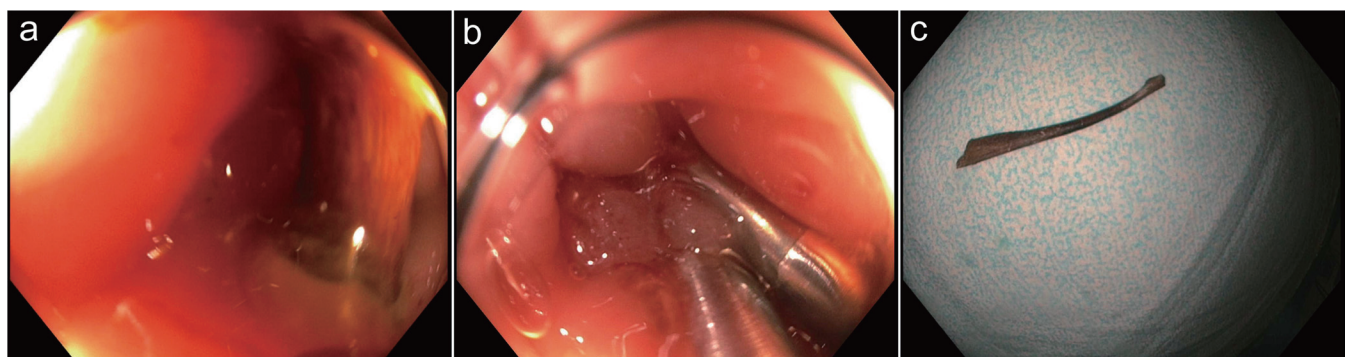


Fig. 2. Images obtained at the colonoscopy. (a) Colonoscopy image: Foreign body wedged into the sigmoid colon wall. (b) Colonoscopy image: Endoscopic clips were placed at the site of the foreign body after removal. c. Image of chicken bone 4.2 cm. in size after removal.

and can be a serious, life-threatening condition. GI tract foreign body ingestion most often occurs in young children, the elderly, and mentally challenged individuals. Risk factors for foreign body ingestion include developmental delay, alcohol intoxication, psychiatric illness, dementia, and incarceration. The most commonly ingested foreign objects are chicken bones and bone fragments, dentures, fish bones, magnets, medication blister packs, toothpicks, and cocktail sticks. Ingestion of sharp and pointed objects increases the risk of perforation. Complications such as impaction, obstruction, and perforation usually occur at sites of gastrointestinal tract angulation or narrowing. The most common locations of lower GI tract foreign body perforation are the ileocecal and rectosigmoid regions of the colon.^{7–10} Several factors are important in the development of gastrointestinal perforation, including the length and sharpness of the object, the motility of the gastrointestinal tract, and the time it takes for an object to pass through all layers of the intestinal wall. Important factors for inflammation and penetration into adjacent organs include the time for severe inflammation to occur within the abdomen and the time for penetration through the wall of adjacent structures.

Studies have shown that the mean time for foreign body perforation is 10.4 days. Using criteria from scintigraphy and wireless capsule endoscopy, the rate of bowel transit has been quantified. Normal whole gut transit time can vary from 14 to 73 h. These times depend on the type of meal and factors that may slow peristalsis, such as a history of diverticulosis coli and pelvic or abdominal invasive surgeries and the resultant intra-abdominal adhesions.^{11,12} For an object to perforate a portion of the digestive tract, it must remain lodged in the area long enough to erode through the four layers of the intestine. To penetrate and perforate adjacent structures such as the uterus, a thick-walled organ, the object must be present long enough to penetrate the entire wall of the organ.

The clinical presentation of foreign body perforation is variable and generally includes abdominal pain, changes in bowel habits, and signs of peritonitis. GI tract perforation is a common cause of an acute abdomen that usually requires immediate surgical intervention. The overall mortality from large bowel perforation has been reported between 16.9% and 19.6%, emphasizing the importance of making an accurate, timely diagnosis. CT imaging can determine the site and cause of perforation with an accuracy of 86%.^{1,2,7} The outcome is usually poor when the diagnosis is delayed. In the absence of radiographic evidence but with a strong suspicion of a foreign body, an endoscopic study should be performed urgently to rule out inherently non-opaque or insufficiently opaque foreign bodies not visible on radiographs and CT scans. Although endoscopy is the usual technique for the treatment of foreign body impaction or obstruction in the upper GI tract, it is not typically considered for lower intestinal perforation. Surgery, either by open technique or laparoscopic approach, is the usual treatment of choice for gastrointestinal perforations, especially with extension into adjacent structures or the presence of peritonitis.^{3,12}

Although colovaginal foreign body perforation has been reported, this is the first reported case of colouterine foreign body perforation. Furthermore, this is the first reported case of a colouterine perforation treated endoscopically. In the present case, the patient had dementia and diverticulosis coli. The foreign body perforation occurred in the mid-sigmoid colon by a 4.2 cm chicken bone and extended beyond the sigmoid colon wall, through the adjacent mesenteric fat, with the tip appearing within the lower uterine segment, possibly within a diverticulum. Most likely, the foreign body penetrated through a colonic diverticulum into the uterus below the peritoneal reflection, as it presented with abdominal and rec-

tal pain without evidence of free intraperitoneal air, peritonitis, or abscess formation. When sharp objects have migrated beyond the ligament of Treitz, as in this case, the course of action is ambiguous. Conventional practice advocates for surgical intervention if the object has not passed after three to four days. In this case, the six-day delay allowed for the colonic perforation and penetration into the uterus to occur.

Endoscopic foreign body removal has been well described. Additionally, endoscopic repair of colon perforation has been documented.^{13–15} However, colouterine perforation with endoscopic perforation into the uterus by a sharp foreign body, as in this case, has not been previously described, and most certainly, endoscopic repair of such an injury has not been previously reported. Once the foreign body was removed, the repair was easily performed using endoscopic clips. Follow-up imaging to reassess for complications and residual material revealed complete resolution and an excellent outcome.

This case was instructive for several reasons. Firstly, it demonstrated that colouterine perforation can occur. It also showed that the six-day delay most likely allowed for the foreign body colonic perforation and penetration by the chicken bone into the uterus. Therefore, earlier treatment and an attempt at endoscopic removal would have prevented the colouterine perforation. This report demonstrates that endoscopic removal of a foreign body with perforation into an adjacent organ, such as the uterus, is safe and effective in selected cases. Significant contraindications to endoscopic removal would include clinical deterioration, penetration of blood vessels, free intraperitoneal air suggesting a peritoneal leak, peritonitis, and abscess formation. Therefore, endoscopic foreign body treatment of colouterine perforation is possible and should be considered as an alternative approach to surgery in a patient with an accessible lesion and without significant contraindications, by a well-trained endoscopist in foreign body removal.

Conclusions

Foreign body ingestion carries the risk of colouterine perforation. Endoscopic treatment of colouterine perforation is possible and provides a minimally invasive, safe, and efficient means of removing a sharp penetrating object, thereby avoiding the inherent risks and need for surgery. It should be considered as the initial approach for patients with an accessible lesion and without significant contraindications.

Acknowledgments

None.

Funding

None.

Conflict of interest

None.

Author contributions

Contributed to study concept and design (MMC, NAC), acquisition of the data (MMC and NAC), performance of the procedure (MMC), drafting of the manuscript (MMC), critical revision of the manuscript (MMC), supervision (MMC).

Ethical statement

The study was performed in accordance with the ethical standards of the Vagelos College of Physicians and Surgeons, Columbia University and White Plains Hospital and with the Declaration of Helsinki (as revised in 2013). Written informed consent was obtained from the patient's family for publication of this case report.

References

- [1] Ma T, Zheng W, An B, Xia Y, Chen G. Small bowel perforation secondary to foreign body ingestion mimicking acute appendicitis: Case report. *Medicine (Baltimore)* 2019;98(30):e16489. doi:10.1097/MD.00000000000016489, PMID:31348257.
- [2] Hunter TB, Taljanovic MS. Foreign bodies. *Radiographics* 2003;23(3):731–757. doi:10.1148/rg.233025137, PMID:12740473.
- [3] Aggarwal R, Indiran V, Maduraimuthu P. Different etiologies of an unusual disease: Colouterine fistula - Report of two cases. *Indian J Radiol Imaging* 2018;28(1):37–40. doi:10.4103/ijri.IJRI_172_17, PMID:29692524.
- [4] Choi PW. Colouterine fistula caused by diverticulitis of the sigmoid colon. *J Korean Soc Coloproctol* 2012;28(6):321–324. doi:10.3393/jksc.2012.28.6.321, PMID:23346512.
- [5] Sentilhes L, Foulatier O, Verspyck E, Roman H, Scotté M, Marpeau L. Colouterine fistula complicating diverticulitis: a case report and review of the literature. *Eur J Obstet Gynecol Reprod Biol* 2003;110(1):107–110. doi:10.1016/s0301-2115(03)00086-1, PMID:12932884.
- [6] Blake AM, Monga N, Dunn EM. Biliary stent causing colovaginal fistula: case report. *JSLs* 2004;8(1):73–75. PMID:14974669.
- [7] Simonetti I, Puglia M, Tarotto L, Palumbo F, Esposito F, Sciuto A, *et al*. When traditions become dangerous: Intestinal perforation from unusual foreign body-Case report and short literature review. *Eur J Radiol Open* 2019;6:152–155. doi:10.1016/j.ejro.2019.04.002, PMID:31024984.
- [8] Kuzmich S, Burke CJ, Harvey CJ, Kuzmich T, Andrews J, Reading N, *et al*. Perforation of gastrointestinal tract by poorly conspicuous ingested foreign bodies: radiological diagnosis. *Br J Radiol* 2015;88(1050):20150086. doi:10.1259/bjr.20150086, PMID:25827210.
- [9] Yang Z, Wu D, Xiong D, Li Y. Gastrointestinal perforation secondary to accidental ingestion of toothpicks: A series case report. *Medicine (Baltimore)* 2017;96(50):e9066. doi:10.1097/MD.00000000000009066, PMID:29390302.
- [10] Maurer AH. Gastrointestinal Motility, Part 2: Small-Bowel and Colon Transit. *J Nucl Med* 2015;56(9):1395–1400. doi:10.2967/jnumed.113.134551, PMID:26159586.
- [11] Lee YY, Erdogan A, Rao SS. How to assess regional and whole gut transit time with wireless motility capsule. *J Neurogastroenterol Motil* 2014;20(2):265–270. doi:10.5056/jnm.2014.20.2.265, PMID:24840380.
- [12] Rodríguez-Hermosa JJ, Codina-Cazador A, Sirvent JM, Martín A, Gironès J, Garsot E. Surgically treated perforations of the gastrointestinal tract caused by ingested foreign bodies. *Colorectal Dis* 2008;10(7):701–707. doi:10.1111/j.1463-1318.2007.01401.x, PMID:18005196.
- [13] Lin XD, Wu GY, Li SH, Wen ZQ, Zhang F, Yu SP. Removal of a large foreign body in the rectosigmoid colon by colonoscopy using gastrolith forceps. *World J Clin Cases* 2016;4(5):135–137. doi:10.12998/wjcc.v4.i5.135, PMID:27182529.
- [14] Hershman M, Shamah S, Mudireddy P, Glick M. Pointing towards colonoscopy: sharp foreign body removal via colonoscopy. *Ann Gastroenterol* 2017;30(2):254–256. doi:10.20524/aog.2016.0116, PMID:28243052.
- [15] Bekkerman M, Sachdev AH, Andrade J, Twersky Y, Iqbal S. Endoscopic Management of Foreign Bodies in the Gastrointestinal Tract: A Review of the Literature. *Gastroenterol Res Pract* 2016;2016:8520767. doi:10.1155/2016/8520767, PMID:27807447.